


# Class IV Restoration using the VariStrip

Procedure/Study by

Dr. David Hornbrook, DDS, FAACD, FACE



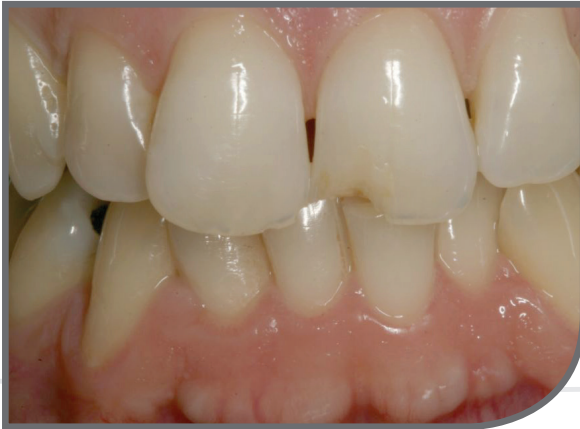

### **Class IV Restoration using the VariStrip**

By David Hornbrook, DDS, FAACD, FACE

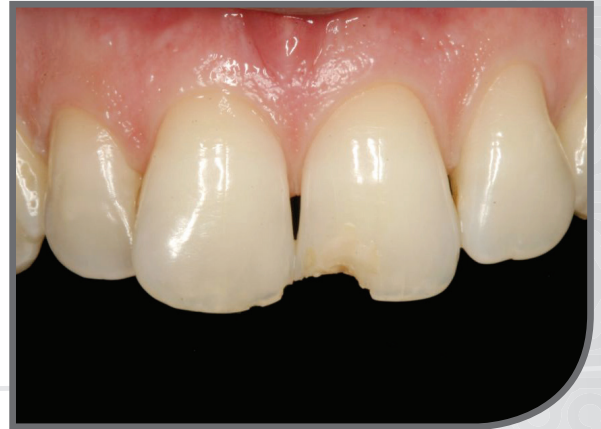Dr. Hornbrook, a gifted clinician and product researcher-turned-mentor, guides meeting participants to the realization that they, too, possess the ability to practice aesthetic dentistry at the very highest level. He is one of dentistry's most famous faces and one of the pioneers of live-patient, hands-on clinical education, as the founder and past director of Pac-live and the Hornbrook Group. He has been a guest faculty member of the post-graduate programs in Cosmetic Dentistry at Baylor, Tufts, SUNY at Buffalo, UMKC, and the UCLA Center of Cosmetic Dentistry. Dr. Hornbrook lectures internationally on all facets of aesthetic and restorative dentistry and has published articles in all of the leading dental journals. A prolific researcher and materials enthusiast, he consults with numerous manufacturers on product development and refinement.

01



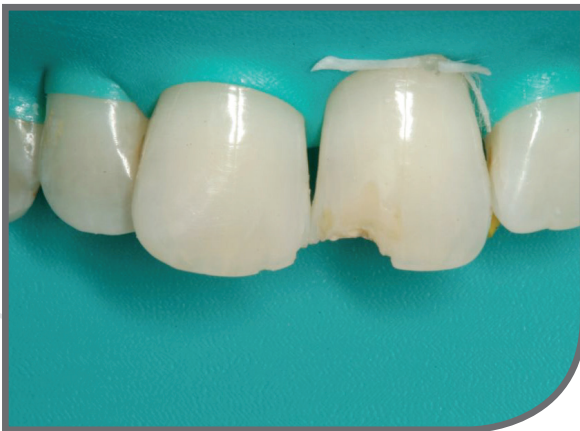Pre-operative view of fractured incisal edge corner of maxillary left central incisor.

02



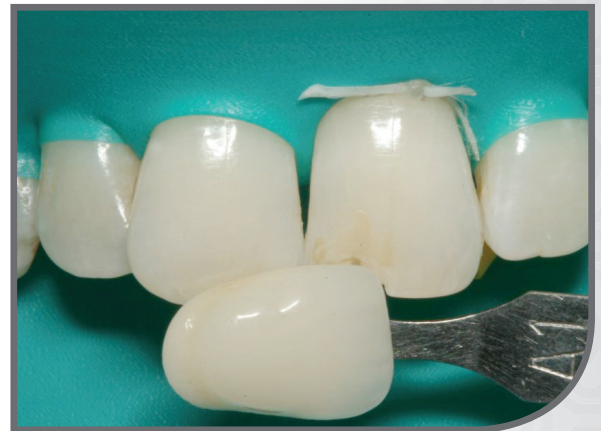Pre-operative view of fractured incisal edge corner of maxillary left central incisor.

03



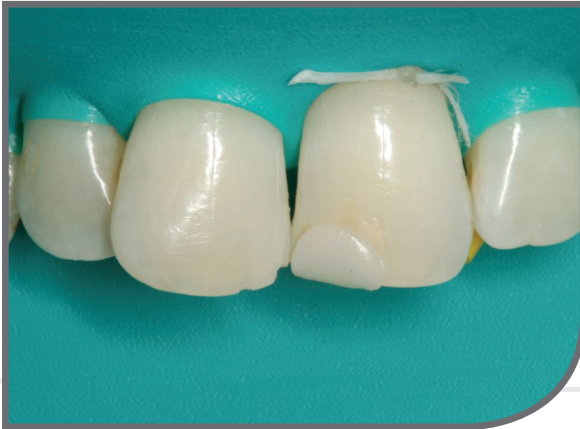Rubber dam isolation of fractured tooth.

04



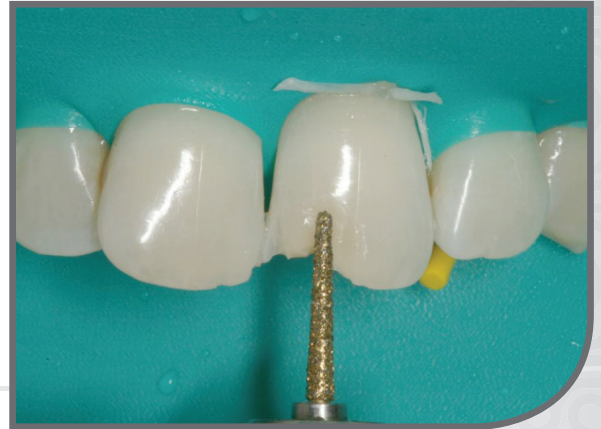Shade check against Vita Shade tab that is keyed to the cured composite shades.

05



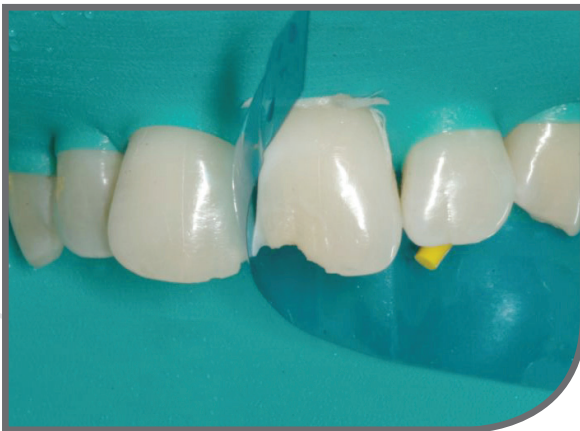Composite resin placed to check for correct shade.

06



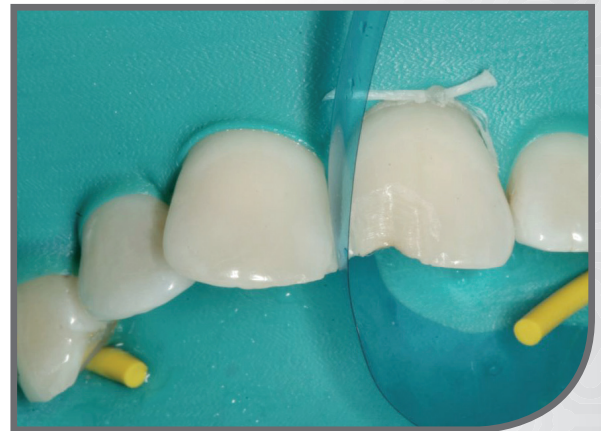Long bevel placed into the enamel to increase surface area for bonding and also to allow better blend of a translucent resin at the tooth-restoration interface.

07



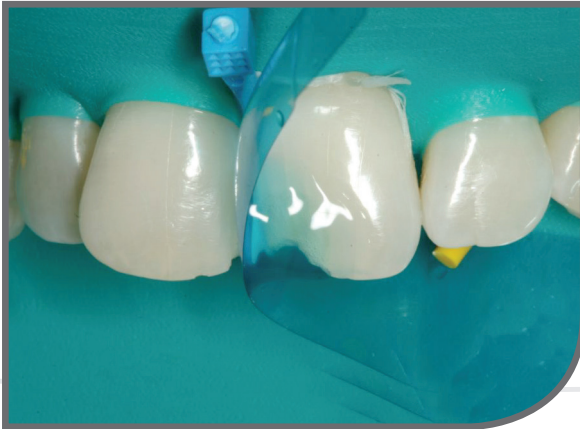Garrison Dental VariStrip placed interproximally.

08



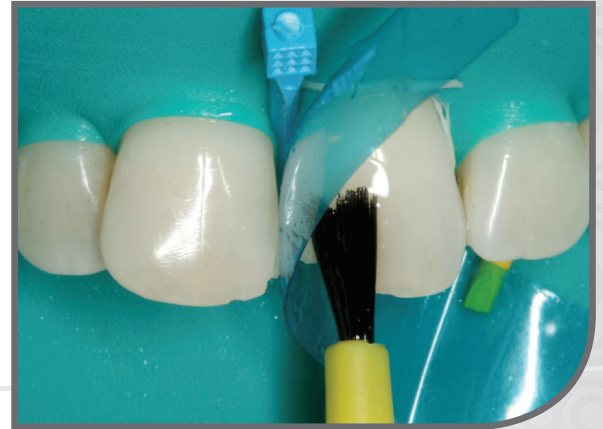VariStrip is precontoured to facilitate a more natural interproximal contour.

09



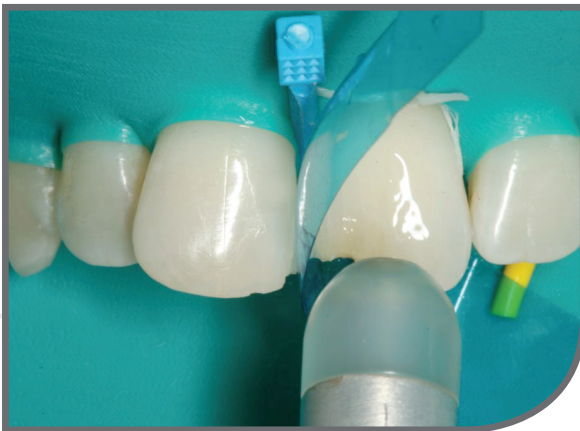Enamel and any exposed dentin is etched with 35% phosphoric acid for 15 seconds.

10



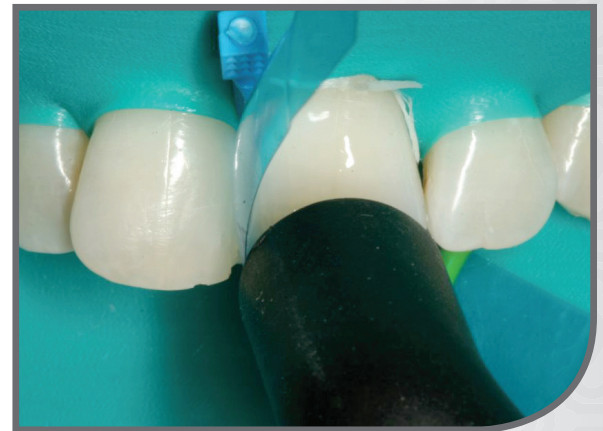Dental primer is applied in multiple layers onto the etched dentin and enamel.

11



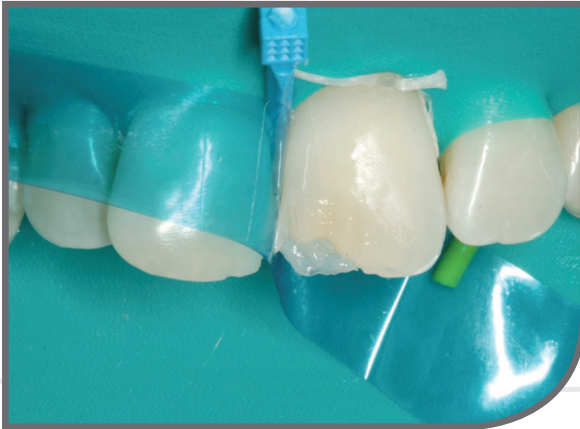The primer is air dried with a moisture-free air source (Adec warm air tooth dryer) to evaporate the volatile, hydrophilic carrier.

12



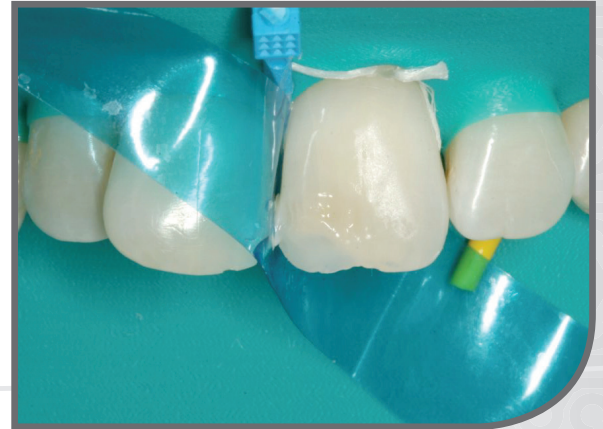Dental adhesive is light polymerized for 10 seconds with a curing light.

13



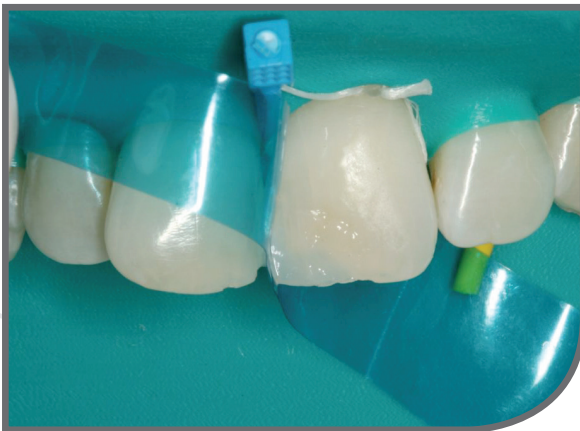Lingual layer of composite resin is placed first. An enamel shade and translucency is used to mimic natural tooth structure.

14



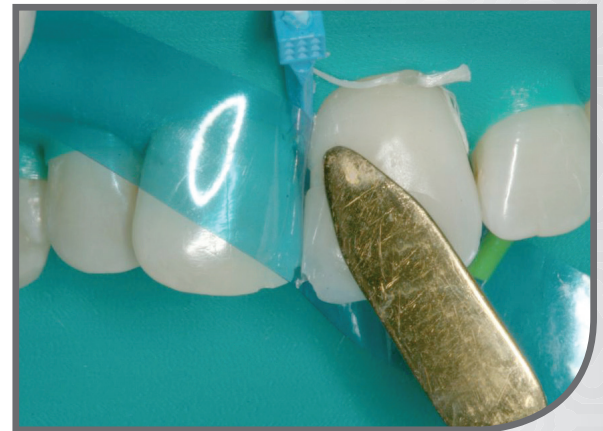A very translucent incisal shade is added to reproduce the natural incisal translucency present in the adjacent tooth.

15



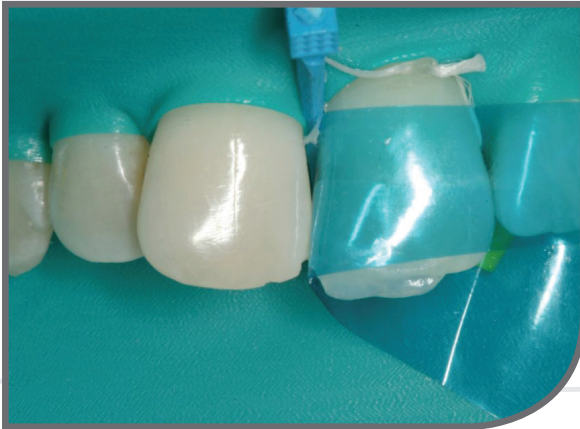A dentin shaded composite resin is added to replace the natural fractured dentin and provide a smooth transition between the restoration and the remaining natural dentin.

16



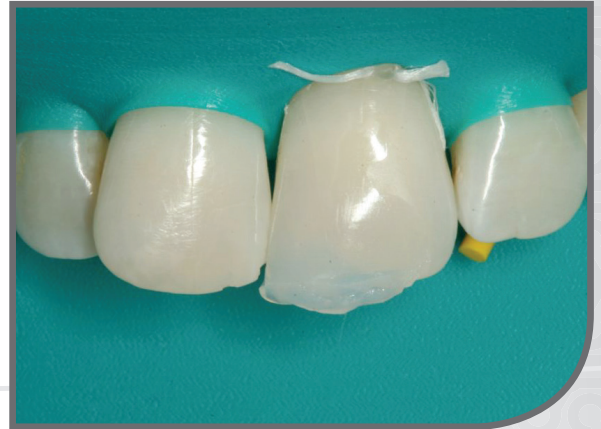A final layer of a translucent enamel layer is added to blend into the natural tooth structure.

17



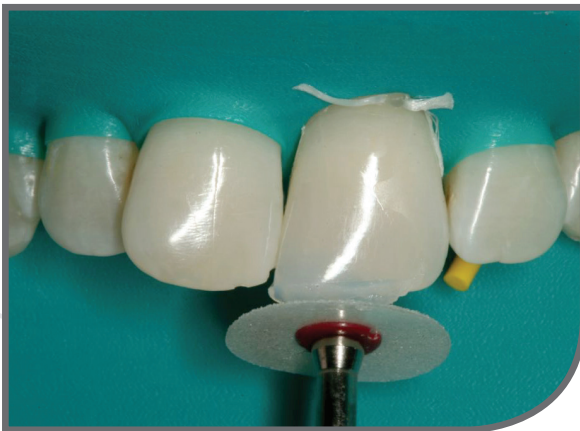The VariStrip can be manipulated to reproduce the adjacent line angle since it is pre-contoured.

18



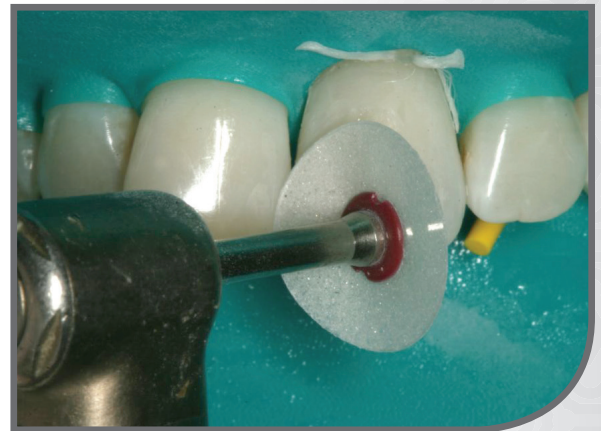After light curing the resin, the VariStrip is removed.

19



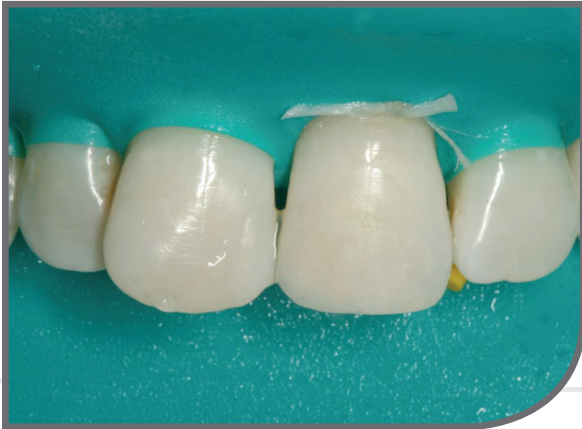The restoration is contoured using discs and diamonds.

20



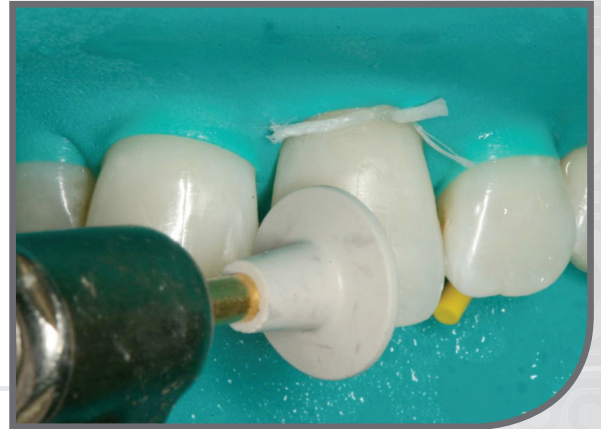The restoration is contoured using discs and diamonds.

21



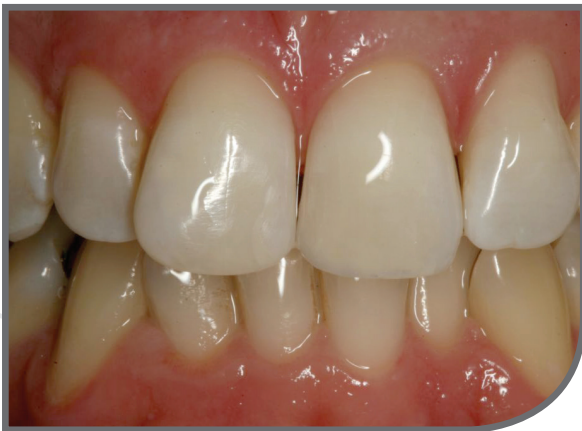Restoration after initial gross shaping.

22



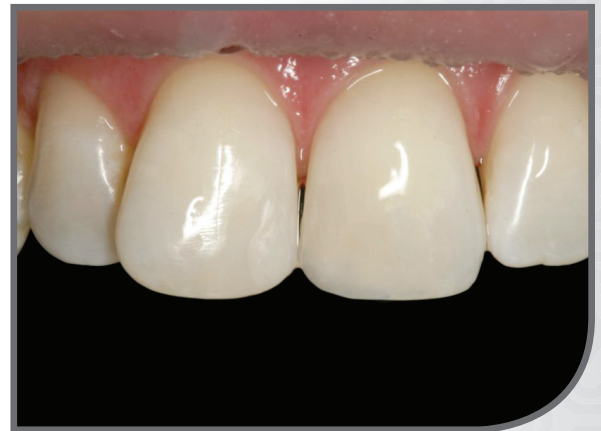Restoration is then polished using rubber polishing points, cups, and discs.

23



Final post-op restoration immediately after placement.

24



Final post-op restoration immediately after placement.





**Garrison**  
Dental Solutions

150 DeWitt Lane  
Spring Lake, MI USA  
49456  
Toll free 888.437.0032

European office:  
Carlstr. 50  
52531 Uebach-Palenberg  
Germany  
Tel. +49 (0) 2451 971 409

[www.garrisondental.com](http://www.garrisondental.com)

CS-000-02-93