

Margin Elevation Technique: #2 and #3 Deep Subgingival Caries

Procedure/Study by

Dr. Matthew A. Nejad, DDS

ReelMatrix 

Garrison
Dental Solutions



Margin Elevation Technique: #2 & # 3 Deep Subgingival Caries

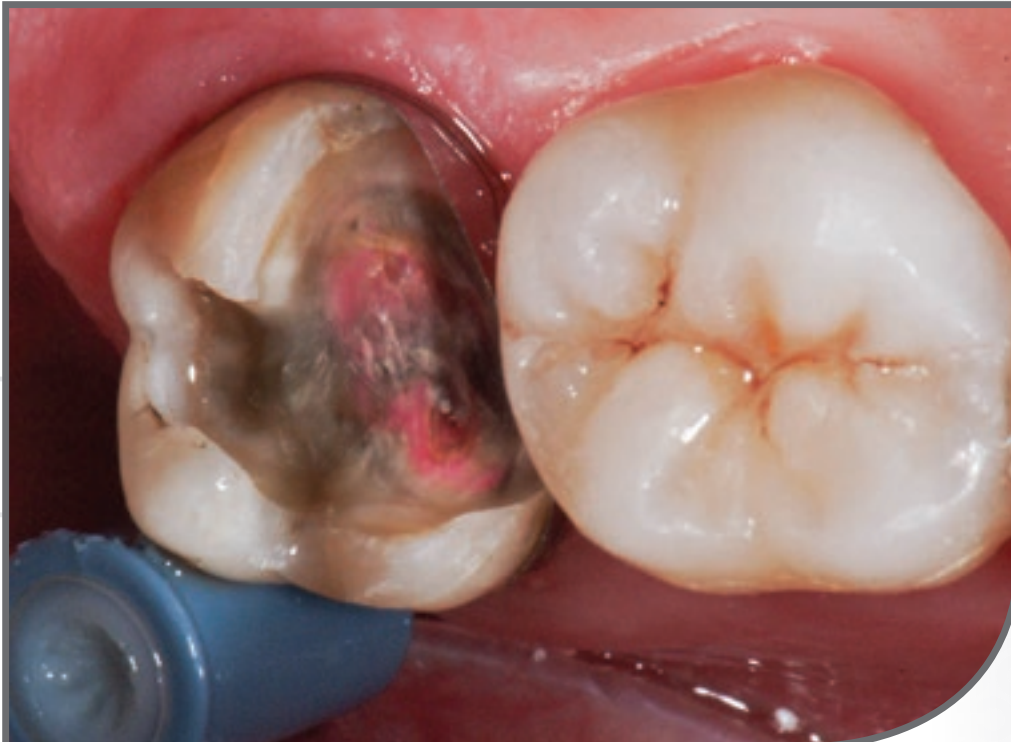Matthew A. Nejad, DDS
Beverly Hills, CA

Dr. Matthew A. Nejad is a graduate of the acclaimed University of Southern California School of Dentistry, the nation's top-ranked school for dentistry. He graduated top of his class with recognition for a record setting amount of fixed prosthodontic procedures completed. During dental school, Dr. Matthew Nejad received advanced training in natural and esthetic dentistry under the mentorship of world-renowned esthetic dentist and "father" of Biomimetic Dentistry, Dr. Pascal Magne.

After graduating, he became heavily involved in academics and became the youngest clinical instructor at the University of Southern California School of Dentistry. He is a leader in Biomimetic Dentistry and provides advanced training for hundreds of dentists from around the world. He conducts research on dental materials and adhesive dentistry with an emphasis on Biomimetic Dentistry.

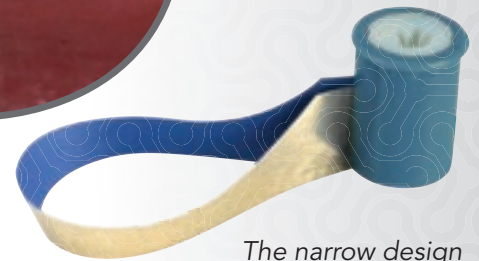Clinical Case:

The margin elevation technique allows proper isolation and elevation of deep margin areas prior to restoring with an indirect partial coverage restoration (inlay or onlay). The use of the Garrison Reel Matrix margin elevation band allows proper adaptation and seal of these deep areas so that a composite margin elevation can be performed.

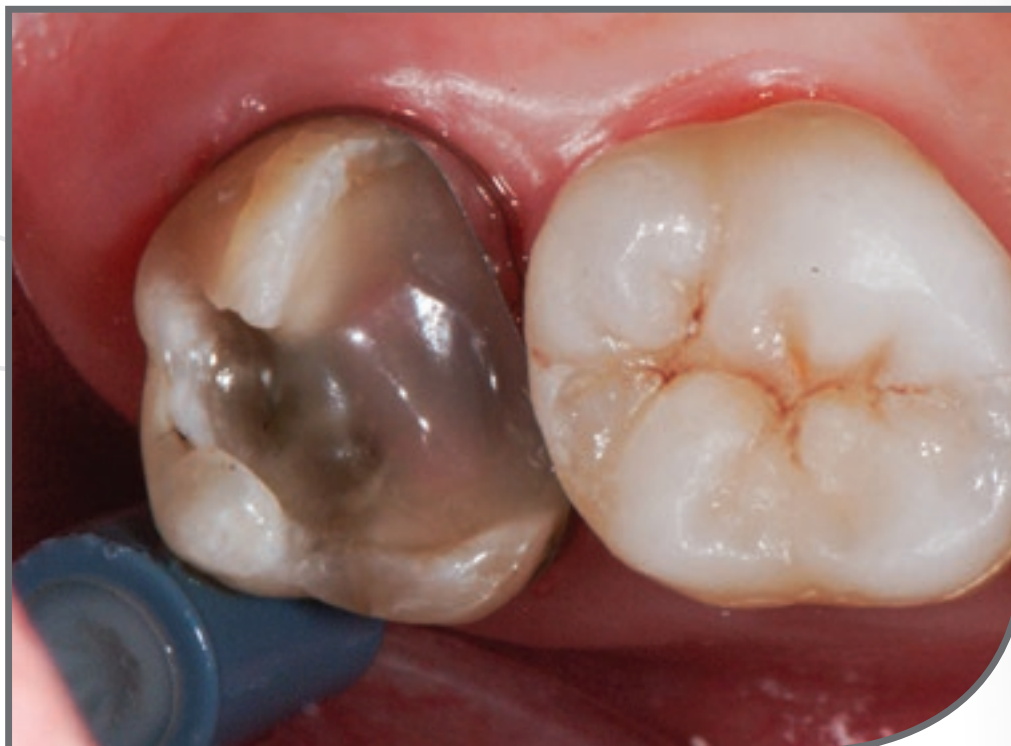

01

#2 and #3 had caries deep subgingival. The margin elevation band is in place, allowing for proper adaptation and seal.

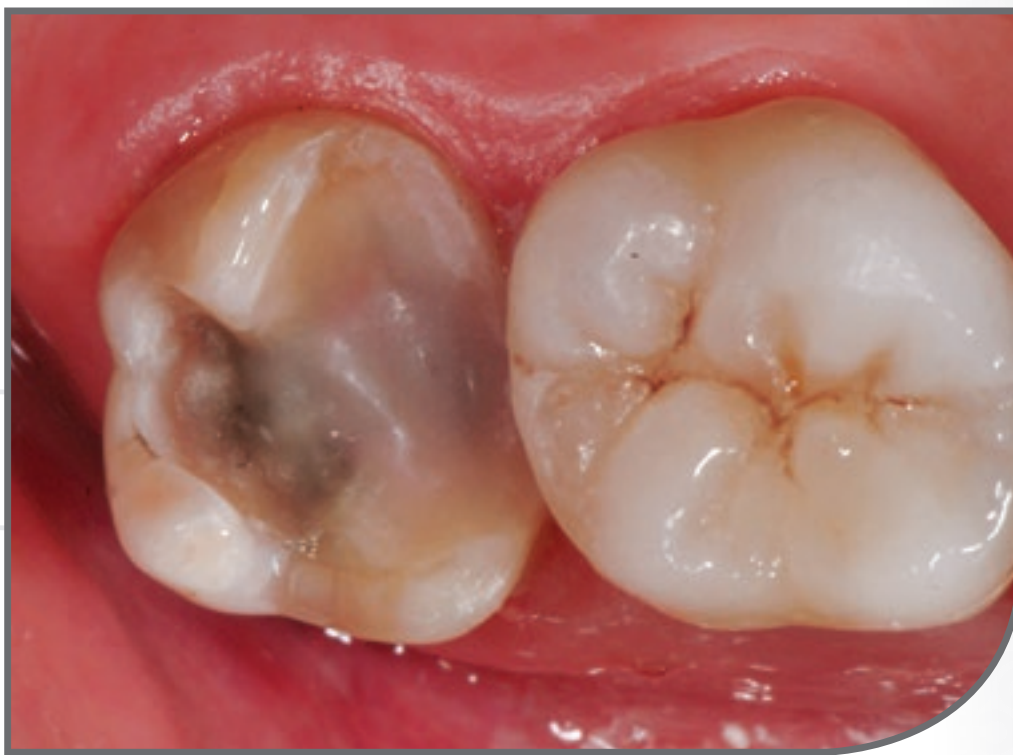

The narrow design of the matrix shape has the ideal contour for adapting to and elevating deep margin areas. The light weight of the Reel Matrix spool allows it to stay in place during the procedure without tipping or falling off as would a heavily weighted traditional retainer.



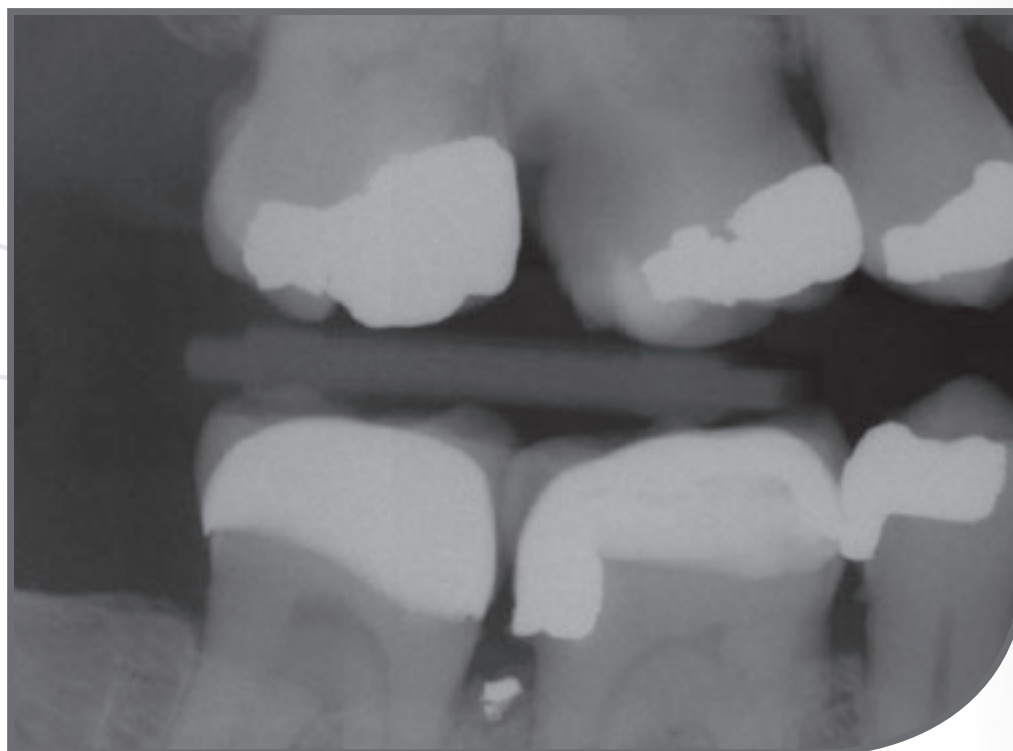
02

Immediate dentin sealing is performed and the deep margin is elevated with composite.



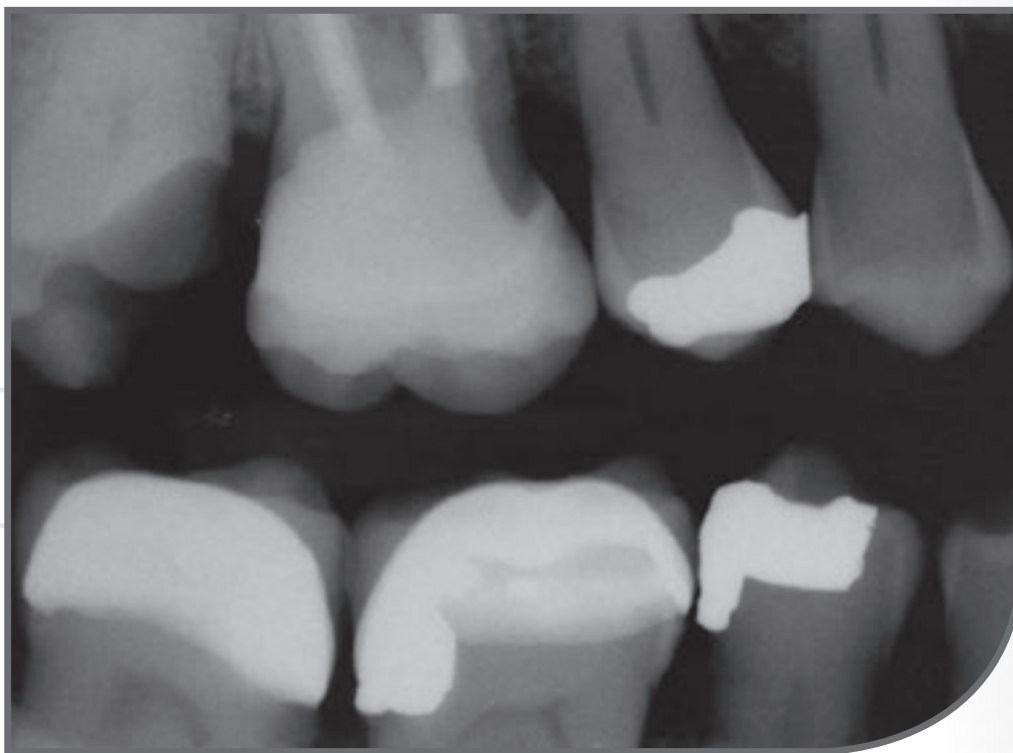
03

When the matrix is removed, very little cleanup is necessary because of the intimate adaptation of the band to the deep subgingival area. Finishing with a #12 blade is recommended to remove any flash.



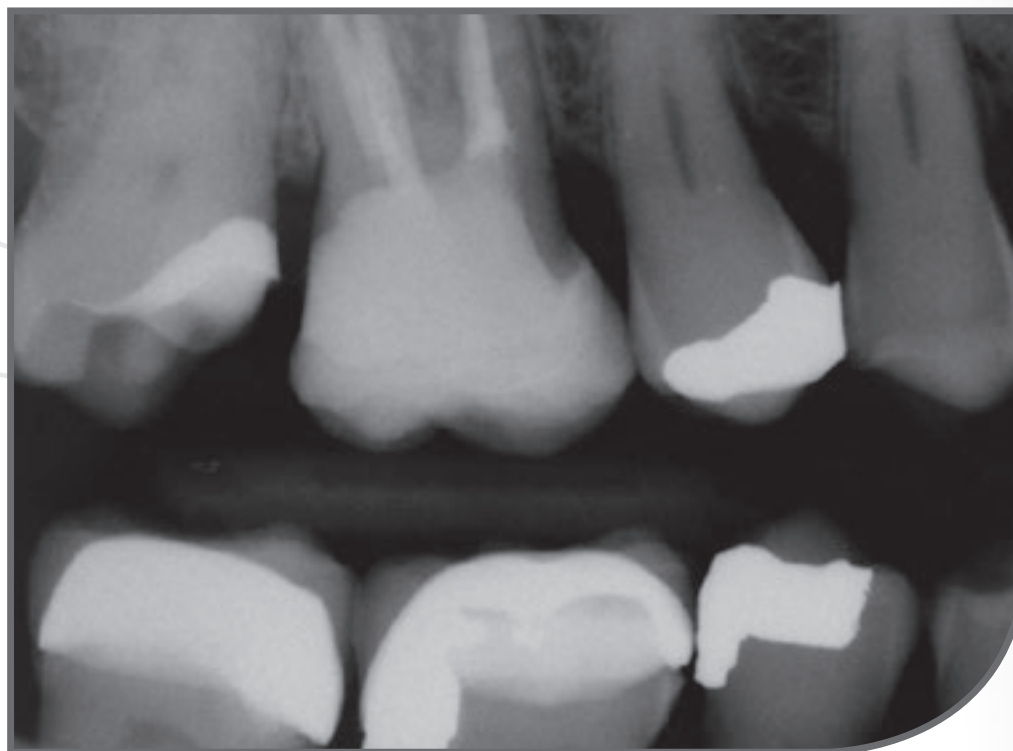
04

Pre-op X-ray. #2 and #3 have deep caries.



05

This x-ray shows a completed margin elevation and an onlay for #3 and the margin location for #2 subgingivally prior to elevation.



06

Shows the completed margin elevation for #2 prior to final restoration being completed.



Garrison
Dental Solutions

150 DeWitt Lane
Spring Lake, MI USA
49456
Toll free 888.437.0032

European office:
Carlstr. 50
52531 Uebach-Palenberg
Germany
Tel. +49 (0) 2451 971 409

www.garrisondental.com

CS-000-02-93